Shear Wave Ultrasound Elastography of the Prostate

Initial Results

Richard G. Barr, MD, PhD,† Richard Memo, MD,*‡ and Carl R. Schaub, MD**

Purpose: This prospective study was to evaluate shear wave elastography (SWE) in the detection of prostate cancer (PC).

Methods: Patients scheduled for a transrectal ultrasound (TRUS) biopsy of the prostate because of elevated prostate-specific antigen levels or abnormal digital rectal examination result underwent a standard TRUS and SWE. A second TRUS examination and sextant biopsy by a second physician blinded to SWE results was then performed. Pathologic result was reviewed, and sensitivity, specificity, negative predictive value (NPV), and positive predictive value (PPV) were calculated.

Results: A total of 53 patients (318 sextants) participated in the study. Mean age was 64.2 years (range, 53–79 years). A total of 26 foci of PC were detected in 11 patients (20.7%). On the basis of the receiver operating characteristic curve, a value of 37 kPa was used as the cutoff between benign and malignant. This produced a sensitivity of 96.2% (25/26), a specificity of 96.2% (281/292), a PPV of 69.4% (25/36), and an NPV of 99.6% (281/282). Six (55%) of 11 false-positive samples were secondary to benign calcifications. The Young modulus of PC ranged from 30 to 110 kPa (mean [SD], 58.0 [20.7] kPa). At the patient level, if a cutoff of 40 kPa was used, all PCs would have been detected, and the positive biopsy rate would be 11 (50%) of 22 compared to 11 (20.8%) of 53 without SWE—a 140% increase in the positive biopsy rate.

Conclusions: Shear wave elastography has a high sensitivity, specificity, PPV, and NPV for the detection of PC. With a high PPV, patients with elevated prostate-specific antigen levels or abnormal results in the digital rectal examination and negative SWE may not require biopsy. This could significantly reduce the negative biopsy rate in PC detection.

Key Words: elastography, prostate cancer, transrectal ultrasound, shear wave imaging, PSA

(*Ultrasound Quarterly* 2012;28:13–20)

Prostate cancer (PC), usually adenocarcinoma of the prostate, is the commonest malignancy in American men (excluding skin cancers) and is second only to lung cancer as a cause of cancer-related death.[1] However, among men diagnosed with the disease, 93% will survive for at least 5 years and 72% will survive for at least 10 years.[1]

Prostate-specific antigen (PSA), measured in serum, has been used as a screening test for PC, with PSA levels above 4.0 ng/mL considered abnormal. In addition to adenocarcinoma, a variety of benign diseases of the prostate (eg, acute prostatitis and benign prostatic hypertrophy) as well as prostatic instrumentation will elevate PSA levels, so false-positive PSA results are common. On the other hand, approximately 20% of PC will present with PSA level less than 4.0 ng/mL.[2,3] A commonly used screening protocol for PC combines serum PSA measurement with digital rectal examination (DRE). The positive predictive value (PPV) of this combination is quoted as 60.6%, an improvement over DRE alone (PPV, 31.4%) or PSA alone (PPV, 42.1%).[3,4] Transrectal ultrasound (TRUS)–guided prostate biopsies are then used to evaluate those patients identified as having abnormal levels by this screening protocol. When sextant biopsies are used, only 25% of these patients will have at least 1 positive biopsy, whereas the biopsy technique will fail to detect tumor in at least 25% of patients proven subsequently to have PC.[5,6]

T2-weighted magnetic resonance imaging and magnetic resonance spectroscopy are also used to diagnose PC. The weaknesses of magnetic resonance imaging are their low sensitivities and their inability to accurately detect tumors smaller than 1 cm in diameter.[7,8] Magnetic resonance spectroscopy also has trouble detecting small tumors owing to their relatively small effect on metabolites.[9] The current set of imaging modalities is not sufficient to properly diagnose PC. One possible solution to this problem is arising in the form of elasticity imaging—or elastography.

Contrast-enhanced ultrasound is also being evaluated for detection and characterization of PC.[10]

Previous studies using strain elastography have demonstrated sensitivity and specificities of 55% to 70%, PPV of 57% to 85%, and negative predictive value (NPV) of 72% to 87%.[11–13] Preliminary studies with shear wave elastography have shown it to possess high sensitivity, high specificity, and high NPV (all >90%) when compared to the current modalities.[14] This high NPV will especially allow patients with high PSA levels but negative elastic examinations to be monitored and spared the usual sextant biopsy.

Elastography Principles

Elastography evaluates tissue stiffness instead of echogenicity. This adds a new method of detecting any pathologic abnormality that could otherwise be missed by conventional ultrasound.[12] Presently, there are 2 types of ultrasound elastography: strain and shear wave. This study used shear wave elastography (SWE). Tissue stiffness is expressed as Young

Received for publication December 14, 2011; accepted January 5, 2012.
*Northeast Ohio Medical University, Rootstown; †Radiology Consultants, Inc, Southwoods Imaging, Youngstown; and ‡Northeastern Ohio Urology, Youngstown, OH.
Dr Barr has received an equipment grant from Supersonic Imagine.
Dr Memo and Dr Schaub have no conflict of interest to declare.
Portions of this study are not approved by the US Food and Drug Administration (FDA). Quantification with shear wave imaging is not presently approved by the FDA. The use of shear wave imaging of the prostate is approved by the FDA without quantification.
Reprints: Richard G. Barr, MD, PhD, 250 DeBartolo Place Bldg B, Youngstown, OH 44512 (e-mail: rgbarr@zoominternet.net).
Copyright © 2012 by Lippincott Williams & Wilkins

Copyright © 2012 Lippincott Williams & Wilkins. Unauthorized reproduction of this article is prohibited.

modulus or simply the ratio of stress put on a material to the tissue deformation caused by the stress.[15] Shear wave is a technique that uses a sonographic push pulse to generate a shear wave in the tissues. Shear wave velocity (V_s) through the tissue is affected by the stiffness, with stiffer tissues allowing it to move faster (Fig. 1).[16,17] The shear wave speed V_s (m/s) or Young modulus (kPa) for each pixel is color coded and overlaid on the B-mode image. A detailed discussion of the differences of strain and shear wave elastography imaging can be found elsewhere.[18]

Prostate Anatomy

The prostate lies in the anterior pelvis and surrounds the middle portion of the male urethra, termed the *prostatic urethra*. It is composed of glandular (exocrine) and stromal tissues. The prostate has been described as having 5 lobes or 4 zones (Fig. 2).[20] Of greatest significance are the zones because they differ significantly in types and frequency of pathologic abnormalities. These 4 zones are the peripheral zone, central zone, transitional zone, and periurethral zone. The peripheral zone is disk-shaped, located anterolaterally, and occupies approximately 70% of the prostate. This is the zone in which 70% to 80% of PC arises, making it a prime target for prostatic surveillance. The central zone is wedge shaped and is located between the urethra and the peripheral zone. It occupies approximately 25% of the prostate and is rarely the site of PC. The transitional zone is made up of 2 separate lobes adjacent to the anterior prostatic urethra. It comprises only 5% of the prostate but is significant because this is the area in which benign prostatic hypertrophy arises in a majority of men later in life. The remaining 10% to 20% of PC arises in the transitional zone.[20]

METHODS

This prospective study was performed under local institutional review board supervision and was in compliance with the Health Insurance Portability and Accountability Act of 1996. Patients scheduled for TRUS biopsy because of an elevated PSA level and/or abnormal DRE result were asked to participate in this study. Transrectal ultrasound was performed on an Aixplorer (SuperSonic Imagine, Aix en Provence, France) with an SE12-3 MHz probe including B-mode, color Doppler, and SWE imaging. The SWE scale is set to a maximum value of 90 kPa. In general, the SWE penetration setting was required because the prostates were enlarged. Imaging was performed in both the axial and transverse planes from seminal vesicles to the apex of the gland. Usually, the field of view of the SWE is not wide enough to evaluate the entire prostate, requiring the right and left lobes be imaged separately. The least amount of pressure on the prostate as possible while maintaining contact with the probe was used in all cases. At each imaging plane, the probe was held steady for approximately 3 to 5 seconds (several frames) to obtain a stabilized image. Measurement of the Young modulus (kPa) was made in every nodule and area with SWE velocity above the baseline prostate tissue. Images were stored digitally.

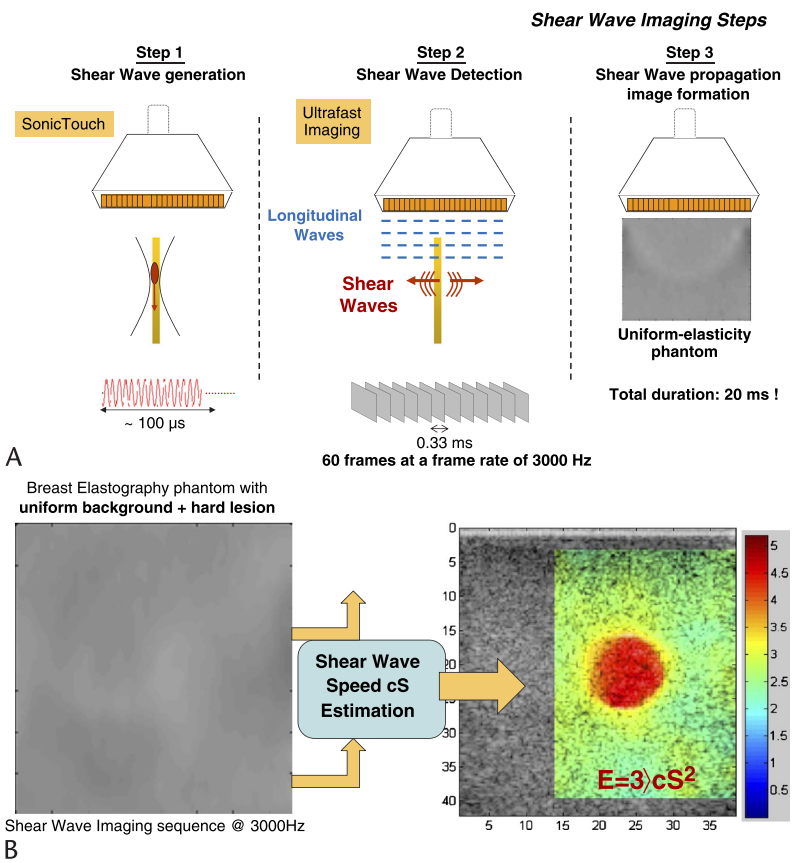

FIGURE 1. A, Technique for SWE. Step 1: The sonographic push pulse being released and propagating a shear wave through the tissue. Step 2: Ultrafast imaging being used to pick up longitudinal wave echoes coming back from the tissue. Step 3: An "elastic map," or phantom, being made based on how fast the echoes came back. The stiffer the tissue the faster the shear wave propagates through them. B, A sample elastic phantom of breast tissue. Note the obvious red foci in the middle of the image. It represents a tumor, which has a higher stiffness value and thus a faster shear wave velocity.

© 2012 Lippincott Williams & Wilkins

Copyright © 2012 Lippincott Williams & Wilkins. Unauthorized reproduction of this article is prohibited.

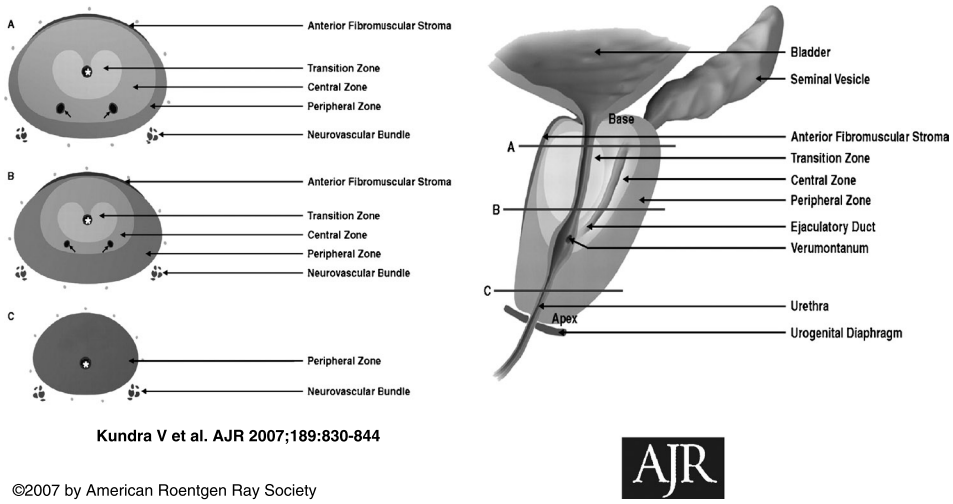

FIGURE 2. Anatomy of the prostate gland. Note the 3 zones and their spatial relationship to one another. The transition zone surrounds the urethra and is the least posterior. It is also the site of BPH, which is why urination is compromised. The peripheral zone is the most posterior and is the thus the easiest to image with elastography. This is useful considering it is a high rate of pathology. Reprinted from Kundra et al[19] by permission of American Roentgen Ray Society.

Nodules and other suspicious areas were noted by the radiologist. Afterward, the urologist performed a DRE, performed a TRUS with S2000 (Siemens Ultrasound, Mountain View, Calif) using an EC 9-4 probe with B-mode ultrasound, and performed sextant biopsy based on standard clinical practice without knowledge of the SWE findings. Prostate volume was calculated using the volume measurement on the ultrasound unit. Any abnormalities on B-mode alone were also examined by biopsy per standard protocol. If abnormalities on the SWE were not included in the original biopsy, additional samples of these areas were obtained after the completion of standard biopsy.

The prostate was divided into sextants for analysis. The central and transitional zones are complex, deep, and often contain calcifications that make interpretation difficult. The peripheral zone lends itself to excellent shear wave imaging. Therefore, we limit our interpretation to the peripheral zone. Nodules identified on B-mode were documented and correlated with SWE values. The SWE and biopsy results were compared for each sextant. Biopsies were staged based on the Gleason score (scale of 2–10). The receiver operating characteristic (ROC) curve was generated using the Young modulus and the pathologic result (benign or malignant). The highest Young modulus value in the sextant was used.

In patients undergoing total prostatectomy, the specimens were sliced in the plane of imaging for correlation with imaging findings.

RESULTS

A total of 53 patients participated in the study, providing 318 sextants. Mean patient age was 64.2 years (range, 53–79 years). Mean PSA level was 5.05 ng/mL (range, 0.21–18.6 ng/mL). A total of 26 foci of cancer were detected in 11 (20.7%) of the 53 patients. Of the 11 patients with cancer, 5 have undergone total prostatectomy for which histologic result was available for comparison.

Pathologic results also included 242 benign prostate tissues, 21 with atypia, 13 with acute prostatitis, and 16 with chronic prostatitis. The results are summarized in Table 1.

The ROC curve of the Young modulus for benign lesions (benign, atypia, acute, and chronic inflammation) and malignant lesions is presented in Figure 3. On the basis of the ROC curve, a value of 37 kPa was used as the cutoff between benign and malignant. This produced a sensitivity of 96.2% (25/26), specificity of 96.2% (281/292), PPV of 69.4% (25/36), and NPV of 99.6% (281/282). Of 11 false-positive samples, 6 (55%) were secondary to calcifications noted on B-mode in benign tissue. The Young modulus of cancers ranged from 30 to 110 kPa, with a mean (SD) value of 58.0 (20.7) kPa. Benign lesions had Young modulus ranging from 9 to 107 kPa, with a mean (SD) value of 21.5 (11.5) kPa.

The Young modulus values of PC were statistically significant compared to each of the benign categories: cancer versus benign ($P < 0.0001$), cancer versus atypia ($P < 0.0001$), cancer versus acute inflammation ($P < 0.0001$), and cancer versus chronic inflammation ($P < 0.0001$). The Young modulus values between benign lesions were all statistically nonsignificant: benign versus atypia ($P = 0.818$), benign versus acute inflammation ($P = 0.606$), benign versus chronic inflammation ($P = 0.0509$), and acute inflammation versus chronic inflammation ($P = 0.096$).

TABLE 1. Summary of Results

n	Pathologic Result	Minimum kPa	Maximum kPa	Mean kPa	SD
242	Benign	9	107	21.2	11.8
21	Atypia	14	38	20.6	5.3
26	Cancer	30	110	58.0	20.7
13	Acute inflammation	9	28	19.5	5.5
16	Chronic inflammation	13	63	27.3	15.5

Copyright © 2012 Lippincott Williams & Wilkins. Unauthorized reproduction of this article is prohibited.

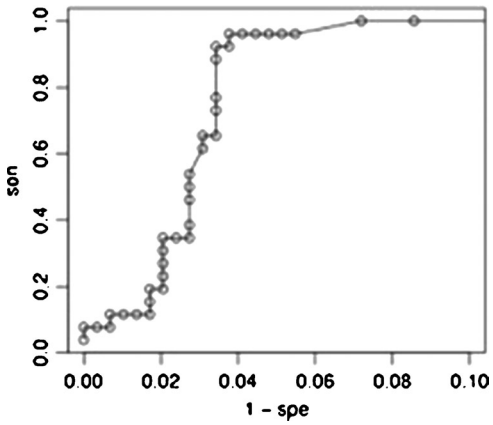

FIGURE 3. The ROC curve for kPa measurements between malignant and benign prostate pathology. With a value of 37 kPa as cutoff, the sensitivity is 96.2%, the specificity is 96.2%, PPV is 69.4%, and NPV is 99.6%.

There were 51 nodules noted on B-mode imaging. Of these, 6 (11.8%) were malignancies on pathology. Of 45 benign lesions, 43 (95.6%) were classified as benign on SWE, and all 6 (100%) malignant lesions were classified as malignant on SWE. There were 2 false-positives, both benign lesions with calcifications. This corresponds to a sensitivity of 100%, specificity of 95.6%, PPV of 75%, and NPV of 100% in SWE predicting malignancy in nodules detected in B-mode imaging.

At the sextant level, to obtain a 100% sensitivity, a cutoff value of 30 kPa is required. At the patient level (patient with cancer of 30 kPa also had 2 other PC foci with 40 kPa), if a cutoff of 40 kPa was used, all cancers would have been detected, and the positive biopsy rate would be 11 (50%) of 22 compared to 11 (20.8%) of 53 without SWE—a 140% increase in the positive biopsy rate.

The shear wave pulse penetrates 3 to 4 cm. In a large prostate, this may not penetrate deep enough to measure the entire peripheral zone (Fig. 4).

Figure 5 is a benign prostate gland in a 74-year-old black man who presented with a PSA level of 12.3 ng/mL. Five years earlier, his PSA level was 8.0 ng/mL. Result from the DRE was unremarkable. Sextant biopsy was negative for disease. B-mode ultrasound was negative for disease, with a prostate volume of 26 mL. On SWE, the peripheral zone is blue, corresponding to a low (<20 kPa) Young modulus throughout.

A selected image from a 65-year-old white man who presents with a PSA level of 4.6 ng/mL is presented in Figure 6. Firmness on the left side of the gland was present on DRE. No abnormality is identified on B-mode or Color Doppler imaging. On SWE, there is a lesion with a high Young modulus of 119 kPa (red). Image-guided biopsy confirms PC with Gleason grade 6.

Figure 7 is a selected image from a 54-year-old white man with a hypoechoic nodule in the peripheral zone. Note that the nodule has a low Young modulus of less than 20 kPa consistent with a benign etiology. However, there is an area of

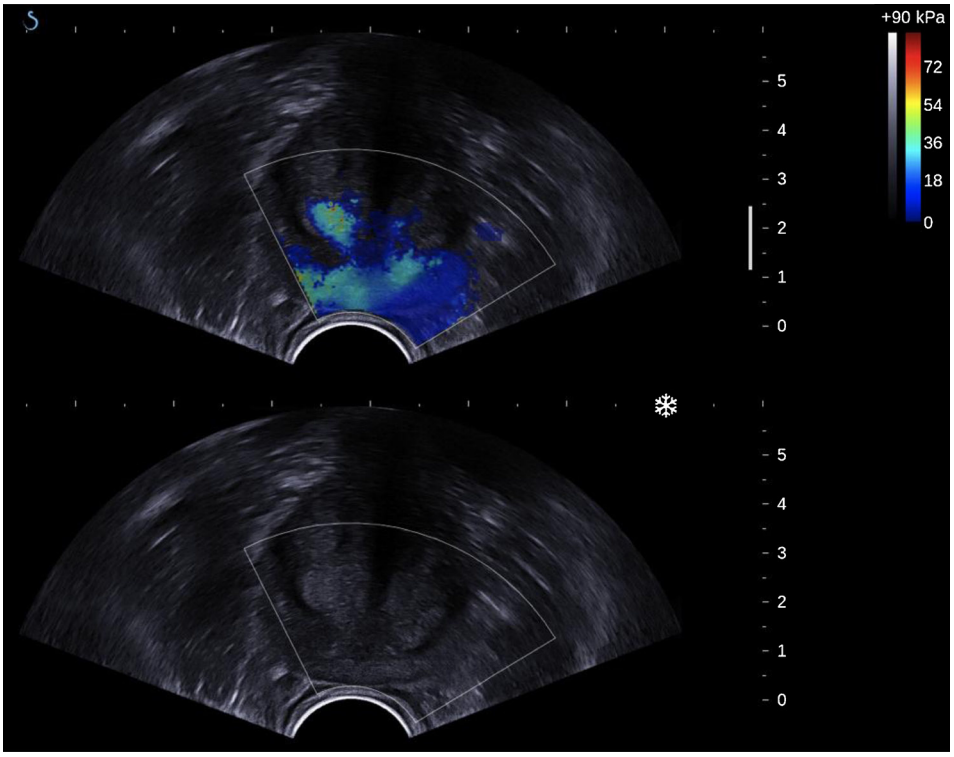

FIGURE 4. Image demonstrating the depth of penetration of the push pulse generating the shear wave. The image on the top is the shear wave image. The image on the bottom is the B-mode image. Measurement of elasticity is expressed as the Young modulus (kPa) displayed on a color scale. In the areas without color in the field of view, the shear wave is not generated, and therefore, the elasticity (stiffness) is not measured.

 © 2012 Lippincott Williams & Wilkins

Copyright © 2012 Lippincott Williams & Wilkins. Unauthorized reproduction of this article is prohibited.

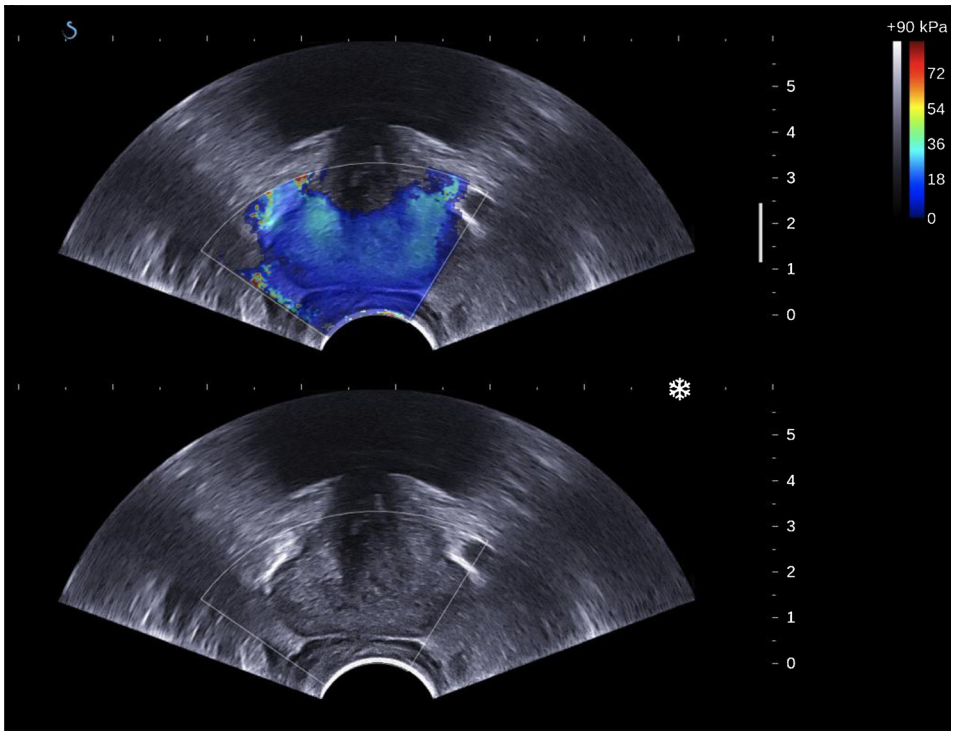

FIGURE 5. A prostate gland of a patient who recently had an elevation of PSA from 8 to 12.3 ng/mL. While increased PSA may be cause for concern, elastic imaging revealed a benign prostate gland. Note the homogenous blue reading, indicative of uniform low stiffness (< 20 kPa) and likely ruling out carcinoma.

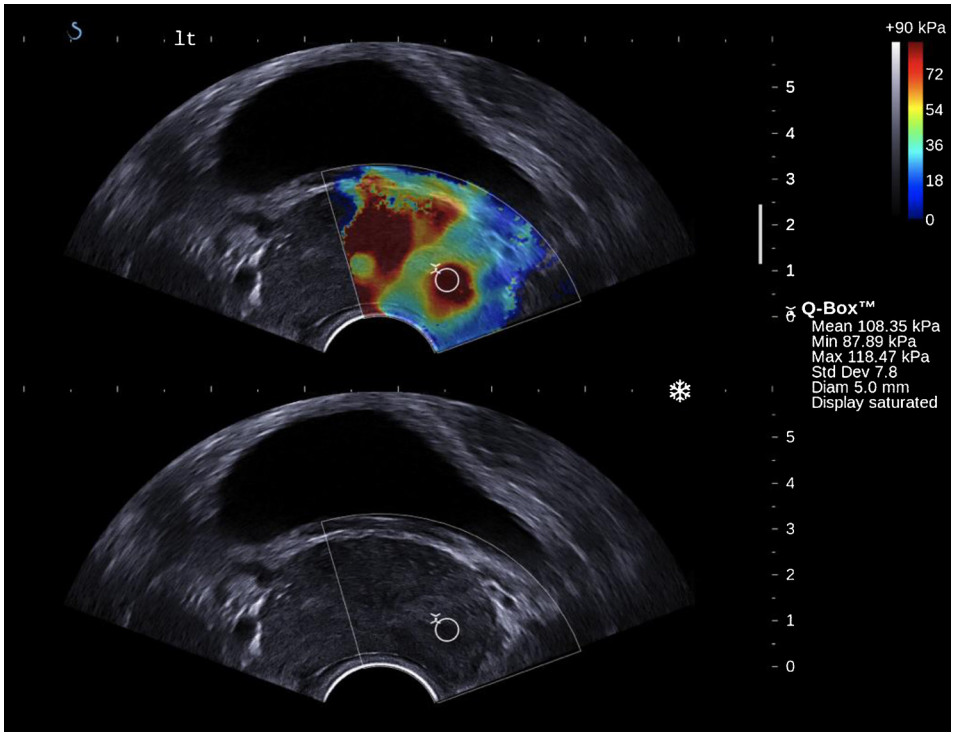

FIGURE 6. True positive for Gleason 6 carcinoma. This patient presented with a low PSA but firm left side on digital rectal exam. B-mode imaging and color Doppler produced no findings. Shear wave elastography presented this image. Note the posterior high stiffness lesion on the left side. This lesion read at a high stiffness (119 kPa) and was confirmed on biopsy to be a Gleason 6 carcinoma.

© 2012 Lippincott Williams & Wilkins

Copyright © 2012 Lippincott Williams & Wilkins. Unauthorized reproduction of this article is prohibited.

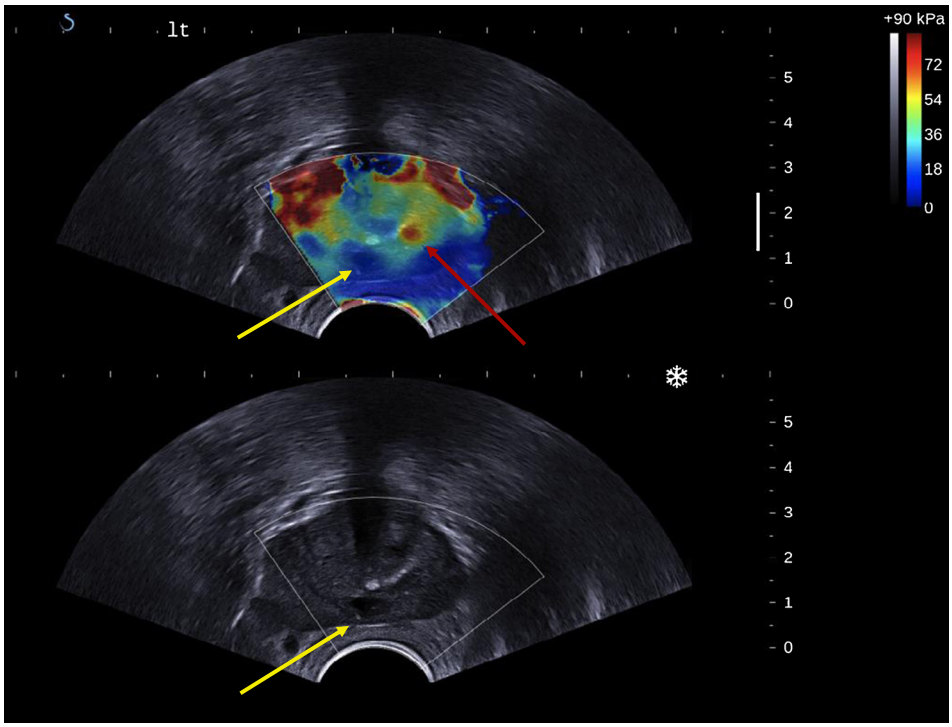

FIGURE 7. Comparison of ultrasound and SWE. This patient presented with a hypoechoic nodule on ultrasound (black lesion with arrow). Shear wave elastography was preformed, and the nodule was found to be of low stiffness (<20 kPa). Note the blue area with a yellow arrow. However, another lesion was found with a high stiffness (75 kPa) and was found on biopsy to be PC with Gleason grade 7. Note the red lesion with a red arrow.

high Young modulus of 75 kPa (red), suggestive of a malignancy. On image-guided biopsy, the hypoechoic nodule was benign, whereas the red area was PC with Gleason grade 7. This highlights the clinical strength of elastic imaging. Malignant lesions can be differentiated from benign prostatic hypertrophy or prostatitis quite easily, because often, their stiffness differs by a factor of 3 and can reach a factor of 10 in extreme cases. Elastography can also be used to guide biopsy of the prostate similar to B-mode imaging.

Calcifications appear as hard nodules on SWE and can lead to false-positive findings (Figs. 8 and 9). Figure 8 is an image from a 68-year-old white man showing an area with a high Young modulus of 73 kPa, suggestive of a malignant lesion. Small echogenic foci consistent with calcifications were noted on B-mode imaging. SWE–guided biopsy of the suspicious area confirms a benign prostatic tissue with focal calcifications. Figure 9 is a selected SWE image from a 56-year-old white man with a focal area of high Young modulus of 67 kPa. SWE–guided biopsy of the lesion revealed acute and chronic inflammation with focal calcifications.

Shear wave elastography can also be used to evaluate for extracapsular extension of tumor. Extracapsular extension of a PC into the seminal vesicles is presented in Figure 10 with the associated pathology on total prostatectomy. The area with a

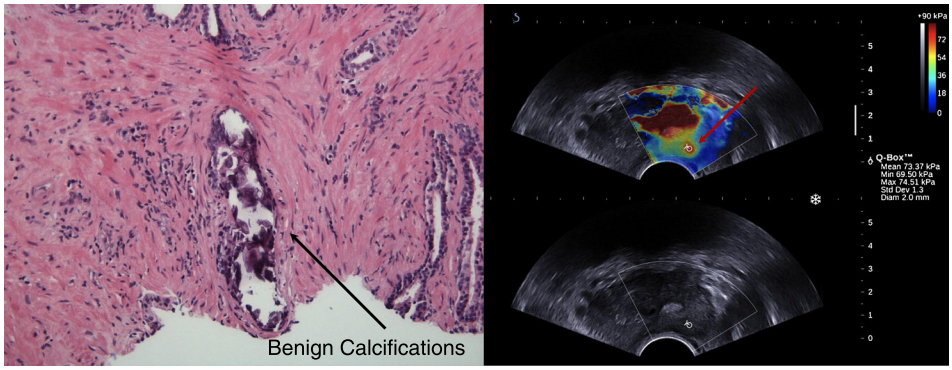

FIGURE 8. False-positive on SWE. This patient had a stiff (73 kPa) and echogenic lesion that suggested malignancy. Note the posterior red lesion circled. Upon biopsy, it was found to be benign prostatic tissue that had been calcified. This highlights a current limitation to SWE.

 © 2012 Lippincott Williams & Wilkins

Copyright © 2012 Lippincott Williams & Wilkins. Unauthorized reproduction of this article is prohibited.

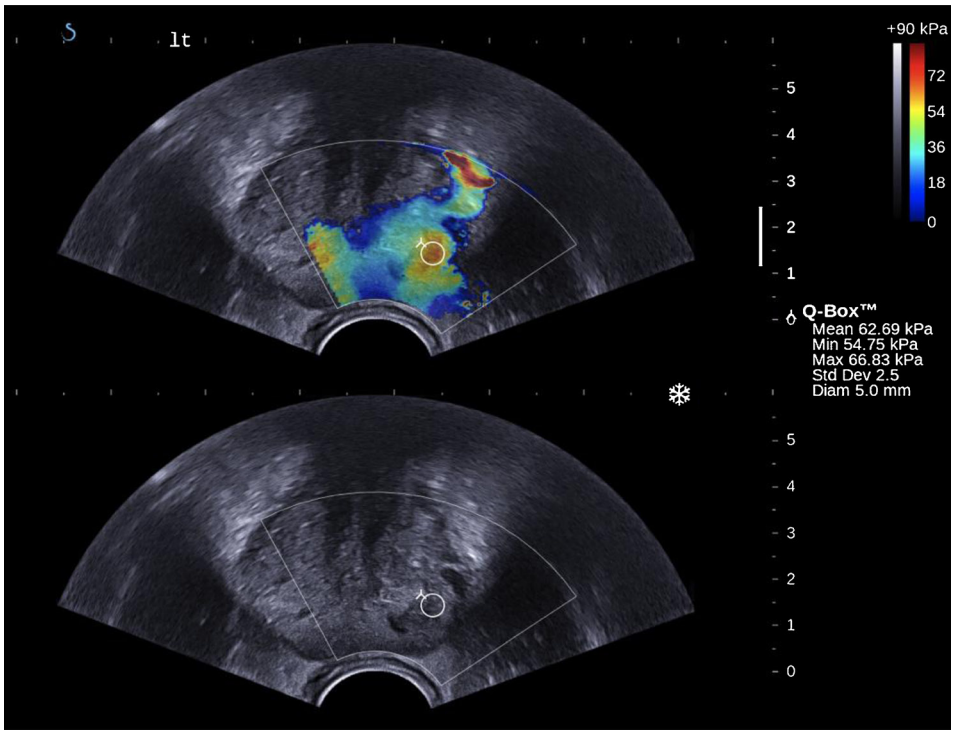

FIGURE 9. False-positive on SWE. This patient had a high (67 kPa) stiffness nodule noted on SWE. Note the posterior yellow-orange area circled. It was found on biopsy to be an inflamed prostatic tissue with focal calcifications, again highlighting a weakness of SWE.

high Young modulus is observed to extend beyond the prostate capsule and into the seminal vesicles on SWE, which was confirmed on surgical pathology.

DISCUSSION

Shear wave elastography is a very promising technique for the detection and biopsy of PC. Additional studies are needed before it can become part of the standard protocol in PC treatment. Of particular interest is its high negative predictive value that may reduce the need for invasive procedures such as biopsies. At present, only 25% to 30% of patients have a positive biopsy. In our study, there was a 20.8% positive biopsy rate. If SWE was used, the biopsy rate could have been decreased by 52.6%, yielding a biopsy rate of 50.0%. Further study needs to be performed to determine whether eliminating calcifications from biopsy is appropriate, which would have improved the biopsy rate to 68.8%. The ability to detect and guide biopsies of areas suspicious for cancer will also help to improve PC detection rates.

This study is limited by relatively small number of cases. Our cutoff value of 37 kPa needs to be validated in a larger

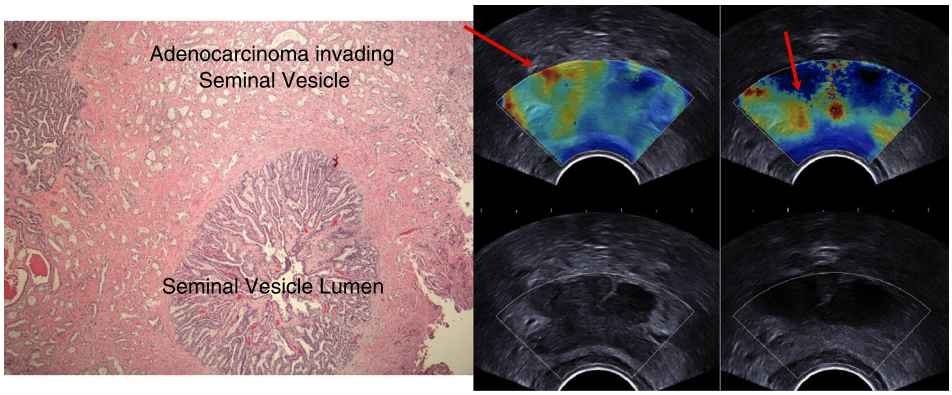

FIGURE 10. A 45-year-old black man with a PSA level of 6.6 ng/mL. On SWE, the PC is identified with a Young modulus of 63 kPa with extension into the right seminal vesicle with a Young modulus of 72 kPa (red arrows). At sextant biopsy, PC was confirmed in the right base. The patient underwent total prostatectomy. Histology at total prostatectomy confirms PC with Gleason grade 7 at the right base extending into the right seminal vesicle.

© 2012 Lippincott Williams & Wilkins

Copyright © 2012 Lippincott Williams & Wilkins. Unauthorized reproduction of this article is prohibited.

multicenter trial. A larger number of cases is required to determine whether the Young modulus is correlated to the tumor grade. Our initial results suggest that shear wave elastography may be more sensitive and specific in diagnosing PC than strain elastography.

Transrectal SWE of the prostate has the potential to become the primary imaging modality for detection of PC. The US Preventive Services Task Force recently advised not to recommend PSA screening because of possible complications of the low positive biopsy rate.[21] Their concern is that the risk of complications negated any benefit of detecting PC. The addition of SWE imaging to PSA and DRE PC screening has the potential to improve the risk/benefit ratio favoring screening.

ACKNOWLEDGMENTS

The authors thank SuperSonic Imagine for an equipment grant which supported this work.

REFERENCES

1. American Cancer Society. *Cancer Facts & Figures*. Atlanta, GA: ACS; 2001.
2. Gormley GJ, Ng J, Cook T, et al. Effect of finasteride on prostate-specific antigen density. *Urology.* 1994;43:53–59.
3. Catalona WJ, Smith DS, Ornstein DK. Prostate cancer detection in men with serum PSA concentrations of 2.6 to 4.0 ng/mL and benign prostate examination: enhancement of specificity with free PSA measurements. *JAMA*. 1997;277:1452–1455.
4. Crawford ED. Prostate Cancer Awareness Week: September 22 to 28, 1997. *CA Cancer J Clin*. 1997;47:288–296.
5. Stroumbakis N, Cookson MS, Reuter VE, et al. Clinical significance of repeat sextant biopsies in prostate cancer patients. *Urology.* 1997;49(suppl 3A):113–118.
6. Cookson MM. Prostate cancer: screening and early detection. *Cancer Control*. 2001;8:133–140.
7. Kwek JW, Thng CH, Tan PH, et al. Phased-array magnetic resonance imaging of the prostate with correlation to radical prostatectomy specimens: local experience. *Asian J Surg*. 2004;27:219–224.
8. Nakashima J, Tanimoto A, Imai Y, et al. Endorectal MRI for prediction of tumor site, tumor size, and local extension of prostate cancer. *Urology.* 2004;64:101–105.
9. Zakian KL, Sircar K, Hricak H, et al. Correlation of proton MR spectroscopic imaging with Gleason score based on step-section pathologic analysis after radical prostatectomy. *Radiology.* 2005;234:804–814.
10. Wink M, Frauscher F, Cosgrove D, et al. Contrast-enhanced ultrasound and prostate cancer; a multicentre European research coordination project. *Eur Urol*. 2008;54:982–993.
11. Ginat DT, Destounis SV, Barr RG, et al. US elastography of breast and prostate lesions. *Radiographics*. 2009;29:2007–2016.
12. Aigner F, Pallwein L, Schocke M, et al. Comparison of real-time sonoelastography with T2-weighted endorectal magnetic resonance imaging for prostate cancer detection. *J Ultrasound Med*. 2011;30:643–649.
13. Giurgiu CR, Manea C, Crisan N, et al. Real-time sonoelastography in the diagnosis of prostate cancer. *Med Ultrason*. 2011;13:5–9.
14. Correas J-M, Khairoune A, Tissier A-M, et al. Trans-rectal quantitative shear wave elastography: application to prostate cancer—a feasibility study. Poster presented at the European Congress of Radiology; March 3–7, 2011; Vienna, Austria. Abstract C-17480.
15. Ophir J, Garra B, Kallel F, et al. Elastographic imaging. *Ultrasound Med Biol*. 2000;26(1):S23–S29.
16. Nelson ED, Slotoroff CB, Gomella LG, et al. Targeted biopsy of the prostate: the impact of color Doppler imaging and elastography on prostate cancer detection and Gleason score. *Urology.* 2007;70:1136–1140.
17. Ophir J, Alam SK, Garra BS, et al. Elastography: imaging the elastic properties of soft tissues with ultrasound. *J Med Ultrasonics*. 2002;29:155–171.
18. Barr RG. Breast elastography: a primer. *J Ultrasound Med*. 2012. In press.
19. Kundra V, Silverman PM, Matin SF, et al. Imaging in oncology from the University of Texas M. D. Anderson Cancer Center: diagnosis, staging, and surveillance of prostate cancer. *AJR Am J Roentgenol*. 2007;189:830–844.
20. Amin M, Khalid A, Tazeen N, et al. Zonal anatomy of the prostate. *Ann KEMU.* 2010;16:3.
21. Chou R, Croswell JM, Dana T, et al. Screening for prostate cancer. A review of the evidence for the U.S. Preventive Services Task Force. *Ann Intern Med*. 2011;155:762–771.

 © 2012 Lippincott Williams & Wilkins

Copyright © 2012 Lippincott Williams & Wilkins. Unauthorized reproduction of this article is prohibited.